



INTERVENTIONAL CASE STUDY: ISOLATED THROMBOLYSIS FOR PAINFUL ILIOFEMORAL DVT.

Interventional Radiologist

Peter B. Hathaway, M.D.

History

A 32 year-old female presented with a two-week history of severe pain and swelling in the left leg secondary to DVT. She was non-ambulatory despite anticoagulation and pain medications. Interventional Radiology was consulted for treatment of ilio-femoral-popliteal DVT.

Procedure

The left popliteal vein was accessed using a 9 Fr. sheath. Venography showed extensive DVT with obstructed pelvic venous outflow (Figure 1).

A 30cm treatment zone Trellis[®]-8 device was positioned from the inferior vena cava to the femoral vein. A 4mg dose of t-PA was administered over a 10 minute device treatment time and the dissolved thrombus was aspirated. Two additional runs of 4mg/10 minutes were then used to treat the femoral-popliteal veins. Venography showed complete removal of the ilio-femoral-popliteal thrombus (Figure 2), with stenosis of the iliac vein (May-Thurner Syndrome) (Figure 3).

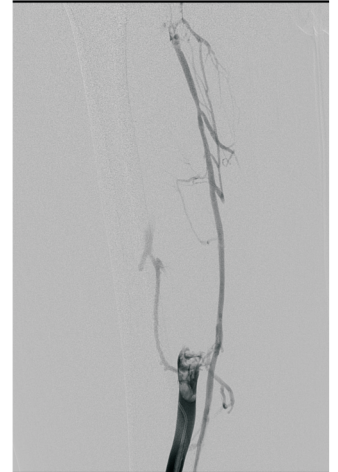


Figure 1

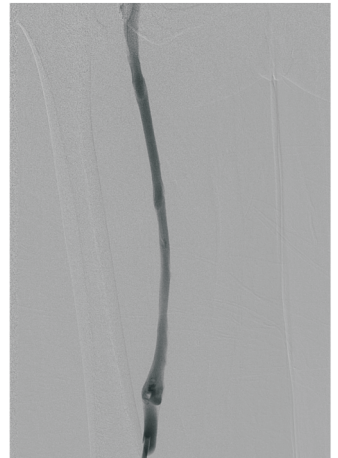


Figure 2

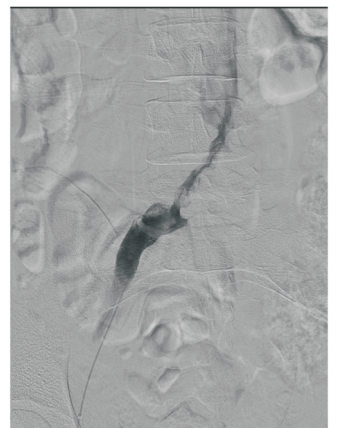


Figure 3



(Procedure Continued)

Angioplasty and placement of a 14mm Wallstent[®] were used to treat the stenotic vein. Post procedure venography showed >95% venous patency and relief of the pelvic outflow obstruction (Figure 4).

Systemic anticoagulation was continued during and after the procedure. She was discharged the following day and has been asymptomatic for two years.

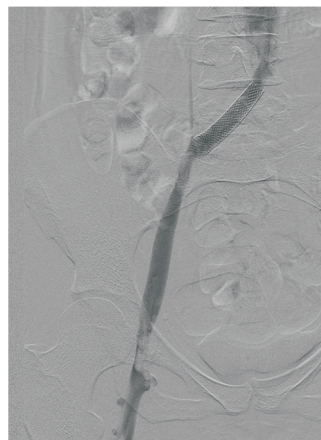


Figure 4

Conclusion

Studies have shown accelerated symptom relief and decreased risk of post-phlebotic syndrome following thrombolysis. Technological innovations have made restoration of lower extremity venous outflow and DVT thrombolysis achievable in a single setting with no ICU stay required.

Learn More

For more information about isolated thrombolysis, call Utah Vascular Clinic at (801) 281-0027. Or visit us online at:
www.utahvascularclinic.com



LANCE ARNDER, M.D.
PAUL ASMAR, M.D.
ROBERT BELL, M.D.
ROBERT BRINTON, M.D.
CRAIG CARPENTER, M.D.
MARK FRUIN, M.D.
MARYELLYN GILFEATHER, M.D.
MICHAEL HANDLON, M.D.
PETER HATHAWAY, M.D.
RICHARD HOLT, M.D.
STEVEN LEE, M.D.
RONALD MILLER, M.D.
EDWARD MINEAU, M.D.
SEAN MULDOWNNEY, M.D.
JONATHAN NAATZ, M.D.
KATHLEEN O'NEIL, M.D.
TRAVIS SNYDER, M.D.
TED SWALLOW, M.D.
PAUL WEISS, M.D.
ED HUNTER, PA-C

SERVING

JORDAN VALLEY HOSPITAL
ST. MARK'S HOSPITAL
SALT LAKE REGIONAL
MEDICAL CENTER